11th Batch NEU MCQ

Questions

1. Spina bifida results due to failure of fusion
    A. Neural tube
    B. Vertebral arches
    C. Anterior neuropore
    D. Vertebral bodies
    E. Posterior neuropore

Ans: B

2. Which of the following agents/diseases is more frequently isolated/ diagnosed among neonates admitted to pediatric intensive care suffering from meningoencephalitis?
    A. Measles
    B. Tuberculosis
    C. Herpes simplex
    D. N meningitides
    E. Mumps

Ans: C

3. A 60-year-old male with long history of alcohol addiction is seeking help. He was diagnosed with advanced chronic liver disease and he is being treated for that. What is the drug of use in his case to treat addiction?
    A. Disulfiram
    B. Naltrexone
    C. Naloxone
    D. Acamprosate
    E. Topiramate

Ans: D

4. The attached diagram represents the mechanism of action of drug X and drug Y, Identify these two drugs

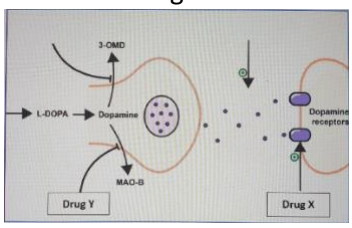

    A. Drug x pramipexole, Drug y selegiline
    B. Drug x pramipexole, Drug y benztropine
    C. Drug x apomorphine, Drug y carbidopa
    D. Drug x entacapone, Drug y ropinirole

Ans: A

5. A 21-year-old female was evaluated in the ER for her third suicide attempt in 6 months, she reports very instable relationship with her family and reports feeling empty and moody all the time she had several old scars on her forearm. After the evaluation she was very happy with you and states that you are the only doctor who understands her feelings. What would be the next step in the management?
    A. Refer her for dialectical behavioral therapy DBT
    B. Give her your phone number and ask her to come see you in private clinic
    C. Give her antidepressant and schedule follow up
    D. Schedule a private meeting with her in a restaurant to get to know her better
    E. Start her on a mood stabilizer like lithium

Ans: A

6. Bipolar disorder 2 is characterized by which if the following
    A. Only mania
    B. Hypomania and mania
    C. Hypomania and depression
    D. Mania and depression
    E. Only depression

Ans: C

7. A 62-year-old has noticed changed in the sensation in her legs for the past two years, on examination there is symmetrically decreased sensation over both lower extremities. She also had a non-healing ulceration on her right foot. Recently she was put on renal dialysis. Which of the following findings confirm the diagnosis in this cause?
    A. Positive culture of campylobacter jejuni
    B. Reduced serum levels of vitamin B1
    C. Fasting blood glucose level of 180 mg/dL
    D. Reduced serum levels of vitamin B12
    E. Congo red positive material in the blood vessels of extremities

Ans: C

8. A patient presented to the clinic. An MRI scan showed a demyelinating lesion affecting right basilar part of lower pons. Which if the following defects will be seen in this patient?
    A. Sensory ataxia
    B. Loss of sensation right face
    C. Tremors in right hand
    D. Right facial paralysis with sparing of forehead
    E. Left sided spastic paralysis sparing face

Ans: E

9. A 17-year-old high school female was admitted to the hospital for the second time after her weight fell below 35 kilograms. She talks a great deal about losing control and becoming fat. She diets rigorously and exercises faithfully, and though emaciated in appearance, she insists that her cheeks, abdomen, hips, and thighs are too heavy. Important symptoms and signs associated with this condition include:
   A. striving for thinness
   B. altered body image
   C. amenorrhea
   D. behavioral problems at home
   E. all of the above

Ans: E

10. Discrepancy between arousal and level of awareness is a characteristic of which of the following states?
A. vegetative state
B. catatonia
C. locked in state
D. none of the above
E. coma

Ans: A

11. A 26-year-old man has been receiving quetiapine for the last few years to control symptoms of psychosis. Over the last year he has been gaining excessive weight. Which of the following drugs would be most suitable to continue therapy?
A. Chlorpromazine
B. Ziprasidone
C. Olanzapine
D. Clozapine
E. Risperidone

Ans: B

12. A 52-year-old man dies of aspiration pneumonia after 6-years illness, characterized by progressive, symmetric, muscular weakness. At autopsy, the brain and spinal cord appear normal on gross examination. Microscopic sections show gliosis in the motor cortex, pallor of the lateral corticospinal tracts, and neuronal loss in the anterior horns of the spinal cord. Which of the following genetic abnormalities is most likely to be present in this man?
A. Expansion of CAG repeats
B. Mutation in superoxide dismutase gene (SOD1)
C. a-Synuclein mutation
D. Presence of apolipoprotein E4/E4 alleles
E. Presence of HLA-DR variants, DR2 allele

Ans: B

13. The axons of the spinocerebellar tracts synapse with which one of the following types of cerebellar cells?

A. Purkinje cells
B. basket cells
C. Golgi cells
D. Stellate cells
E. Granule cells

Ans: E

14. A middle-aged, obese man is chronically tired and sleepy. He sleeps 8 hours a night and takes occasional naps. He wakes up every morning with headache and a dry mouth. His wife complains about his loud snoring. Which one of the following is the most appropriate diagnosis?

A. Conversion disorder
B. Major depression
C. Obstructive sleep apnea (OSA)
D. Narcolepsy
E. anxiety

Ans: C

15. Heroin is a therapeutic agent is some countries. Which one of the following is the only indication for its medical use?

A. A 28-year-old male who is already a heroin addict.
B. A 70-year-old male with fracture of femur
C. A 68-year-old terminally ill with severe pain
D. A 32-year-old pregnant female who fails to respond to fentanyl
E. A 38-year-old male with sever biliary colicky pain

Ans: C

16. Blood cell counts are required to be measured on a regular basis when prescribing which of the following antipsychotic drugs?

    A. Risperidone
    B. Aripiprazole
    C. Clonazepam
    D. Clozapine
    E. Haloperidol

Ans: D

17. a junior resident in medicine rapidly treated hyponatremia in a patient. A few days later, the patient developed quadriplegia. The brain MRI would show demyelination of which part of the brain?

A. Crus cerebri of midbrain
B. Posterior limb of internal capsule
C. Basilar part of pons

D. Pyramids of medulla
E. Tegmentum of pons

Ans: C

18. a known heroin addict was brought to the ER in an unconscious state. In order to ascertain the cause of coma. A thorough physical examination was performed. Based on the physical findings, the doctor ruled out heroin as the cause of unconsciousness. Which one of the following findings helped the physician to rule out heroin as the cause of coma in this case?

A. Respiratory depression
B. Mydriasis
C. Bronchoconstriction
D. Vomiting
E. Hypotension

Ans: B

19. A 67-year-old man was admitted for elective surgery 3 days ago, after surgery, he had developed symptoms of increased agitation, irritability, and anger. He is suffering from which one of the following conditions?

A. Diabetes
B. Major depression
C. Seizure disorder
D. Alcohol withdrawal
E. Hospital phobia

Ans: D

20. which of the following five post contrast MRI images is consistent with a case of glioblastoma?

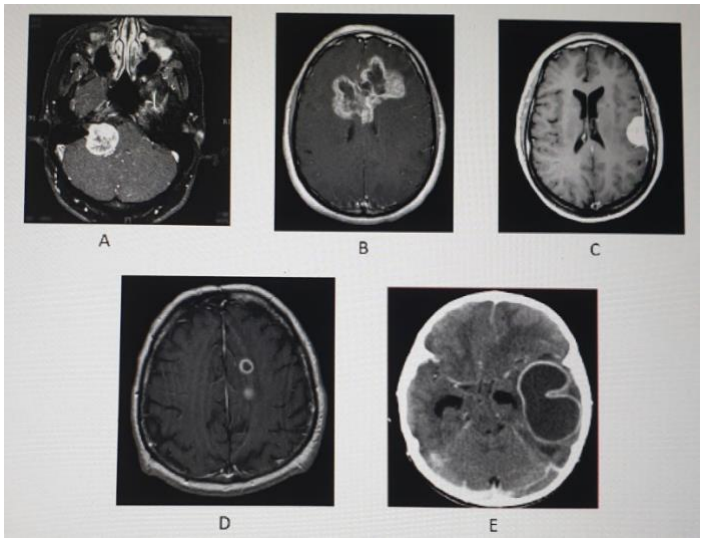

A. C
B. E
C. B
D. A
E. D

Ans: C (the pic labeled B)

21. your female patient has suffered a stroke. She has difficulty copying simple diagrams, even though she hears and understands your requests to do so. You notice that she only has makeup on the right side of her face and does not seem to know where her left hand is in space. Which blood vessel might have been occluded to cause these symptoms?

A. Left anterior cerebral artery
B. Right middle cerebral artery
C. Right anterior cerebral artery
D. Left vertebral artery
E. Right posterior cerebral artery

Ans: B

22. a 45-year old male died due to overdose of heroin. Which one of the following would be most likely the cause of his death?

A. Respiratory depression
B. Acute severe asthma
C. Anaphylaxis
D. Cardiac arrest
E. Cardiac arrhythmia

Ans: A

23. a young child was referred for intelligence testing because he was not doing well in school. He was found to have normal results. An electroencephalogram was done. Which is the most likely finding for EEG?

A. Generalized slow activity
B. 3Hz spike-wave complexes
C. Normal activity
D. Temporal spike activity
E. Rolandic spike activity

Ans: B

24. which one of the following is the cause of watershed infarction?

A. Hypertensive encephalopathy
B. Low cardiac output
C. Artery to artery embolism
D. Subarachnoid hemorrhage
E. Head trauma

Ans: B

25. Protein synthesis is involved in which part of the explicit memory?

A. Consolidation
B. Encoding
C. Storage
D. Retrieval

Ans: A

26. A 52-year-old patient has an infarct involving a branch of the posterior communicating artery, causing damage to the ventral anterior (VA) and ventrolateral (VL) dorsomedial, and anterior thalamic nuclei. The VA nucleus receives inputs primarily from structures associated with which of the following?

A. Autonomic function
B. The regulation of sleep
C. Somatosensory functions
D. Motor Functions
E. Auditory and taste functions

Ans: D

27. Which of the following is a symptomatic treatment of migraine?

A. Metoclopramide
B. Sumatriptan
C. Lasmiditan
D. Dihydroergotamine
E. Timolol

Ans: A

28. A 21-year-old lady complained of headache and diplopia. She had a history of weight gain in the past 2 years. Examination shows left lateral rectus weakness, visual acuity 20:20 OU. Fundus shows papilledema more on the left. What is the most likely diagnosis?

A. Craniopharyngioma
B. Optic neuritis
C. Idiopathic intracranial hypertension
D. Pituitary adenoma
E. Transverse sinus thrombosis

Ans: C

29. Regular use of which of the following substances may contribute to the development of motivational syndrome, feeling stoned and more passive inward personality characteristics?

A. Benzodiazepine
B. Alcohol

C. Amphetamine
D. Cocaine
E. Marijuana

Ans: E

30. Which one of the following peripheral sites express mu receptors?
A. Uterine smooth muscles
B. Bronchial smooth muscles
C. Myocardium
D. GI smooth muscles
E. Vascular smooth muscles

Ans: D

31. A patient was operated for a thoracic aortic aneurysm, which resulted in damage to the intersegmental arteries and resulted in compromised blood supply to the spinal cord. Which of the following signs on neurological examination is indicative of anterior cord syndrome?
A. Loss of vibratory sensation bilaterally below the level of the lesion
B. Bilateral flaccid type of paralysis below the level of lesion
C. Loss of conscious proprioception bilaterally below the site of lesion
D. Contralateral loss of pain and temperature below the level of the lesion
E. Bilateral spastic type of paralysis below the level of lesion

Ans: E

32. Which of the following types of hemorrhages is seen in patients with ruptured intracerebral aneurysms?

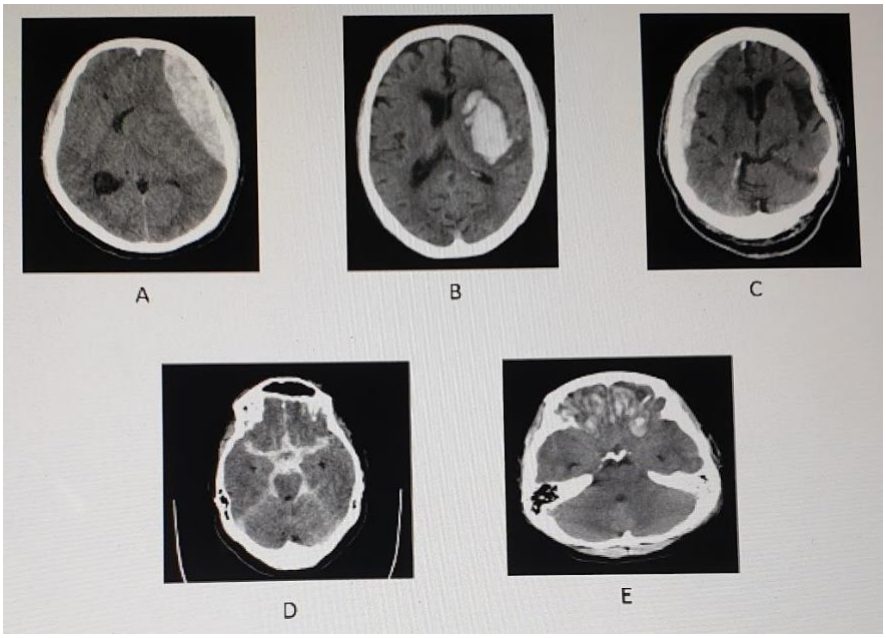

A. B

B. E
C. A
D. C
E. D

Ans: E (the pic labeled D)

33. A 30- year-old patient present with acute abdomen, acute appendicitis was suspected, and he was administered an intravenous analgesic. 15 minutes later, his BP and HR increased, and he complained of a state uneasiness. Which of the following receptors were activated by the analgesic?

A. Delta
B. Alpha
C. Kappa
D. Beta
E. Mu

Ans: C

34. A 40-year-old male who been suffering from a disorder of unknown origin complains to his physician that he has difficulty in producing a smile from the left side of his face, and he can't salivate or produce tears from the left eye. Further analysis showed some loss of taste and that affected muscles were flaccid, and the eyelids were open. The paraganglionic parasympathetic fibers of the nerve involved in this case arise from which of the following?

A. Inferior salivatory nucleus
B. Superior salivatory nucleus
C. Edinger-Westphal nucleus of cranial nerve III
D. Dorsal motor nucleus of the vagus
E. Nucleus ambiguous

Ans: B

35. A 60-year-old patients with sudden onset of abnormal movements in his right limbs came to KFSHRC. He had increased appetite and hyperphagia and also developed mood and behavioral changes. Mental status and cranial nerves function were normal. In examination of motor system, no abnormality was detected in muscle tone; and force of extremities was normal. Deep tendon reflexes were symmetric, and no pathologic reflexes were found. Involuntary movements, including continuous, arrhythmic and purposeless choreiform movements with occasional brisk proximal ballistic movements were affecting both upper and lower limbs on the right side with the same severity. The magnetic resonance showed an infract in the sub-thalamic region. The infract in this case due to occlusion of a branch of which one of the following arteries?

A. Middle cerebral
B. Posterior cerebral
C. Anterior communicating
D. Posterior communicating

E. Anterior cerebral

Ans: B

36. A 22-year-old man with schizophrenia presents with negative symptoms of this disorder. Antagonism at which of the following receptors may have the greatest ability to improve his negative symptoms?

A. Muscarinic
B. Serotonin
C. Nicotinic
D. Glutamate
E. Dopamine

Ans: B

37. Corneal reflex (blink) can be helpful to demonstrate which of the following?

A. Intact midbrain function
B. Absence of peripheral neuropathy
C. Intact medullary function
D. Intact pontine function

Ans: D

38. Ali is a 75-year-old man who is right-handed and was told by the past by his internist that he had an irregular heartbeat. One morning, He awoke to find that his face drooped on the right side, and that he couldn't move his right arm or right leg. He was taken to the hospital and a neurologist was called to see Ali in the emergency room. When he listened to Ali's heart, he detected an irregular heartbeat. It was very difficult to understand Ali's speech, because it was halting, with a tendency to repeat the same phrases over and over. His mouth drooped on the right when he attempted to smile, but his forehead remained symmetric when he wrinkled it. He couldn't move his right arm at all, but he was able to wiggle his right leg a little bit. What kind of language problem Ali has?

A. Pure word deafness
B. Broca's aphasia
C. Alexia
D. Wernicke's aphasia
E. Dysarthria

Ans: B

39. 15-year-old male patient is getting treated with phenytoin for his seizure. He recently two seizures. His physician decides to increase the phenytoin dose because of his recent growth. Three weeks later, he goes complaining not of new incidence of new seizure, but of having trouble walking and feeling dizzy. What is the best explanation for the emergence of his recent symptoms? The patient was not listening to his physician and he was not taking his drug on time.

A. Phenytoin metabolism increased due to induction of liver microsomal enzymes

B. Phenytoin was eliminated by zero order kinetics and reached toxic levels
C. He was taking other drugs which were inhibitors of microsomal enzymes
D. The patient was taking more pills than needed because he was depressed

Ans: B

40. What does CSF analysis usually show in multiple sclerosis?
A. Froin syndrome
B. Elevated protein
C. Xanthochromic appearance
D. Normal protein
E. Decreased protein

Ans: B

41. a 40-year-old man with history of chronic anxiety and drug abuse comes to you with insomnia. He states that he has problems with initiation of sleep. He states that once he falls asleep, it is satisfactory. Which one of the following would be best choice for treating him?
A. Phenobarbitone
B. Temazepam
C. Ramelteon
D. Diazepam
E. Buspirone

Ans: B

42. what is the most common presentation in juvenile myoclonic epilepsy (JME)?
A. Nocturnal generalized tonic clonic seizures
B. Daytime generalized tonic clonic seizures
C. Early morning myoclonus
D. Absence seizures
E. Unilateral convulsions

Ans: C

43. A patient was brought to the ER. A CT scan showed an infarct involving tegmentum of right midbrain at the level of superior colliculus which one of the following clinical presentations is consistent with this lesion?
A. Right sided complete facial paralysis
B. diplopia while walking down the stairs
C. deviation of the right eye to the right
D. left sided spastic hemiplegia spearing the face
E. deviation of the right eye to the left

Ans: C

44. which of the following agents is most likely associated with CSF analysis showing increased lymphocytes increase, increased proteins and normal glucose?

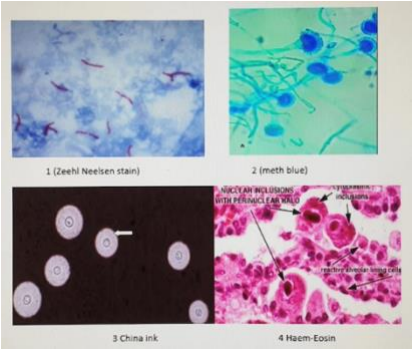

A. 2
B. 5
C. 3
D. 1
E. 4

Ans: E

45. Pathological and chronic warning is the cardinal diagnostic feature of generalized anxiety disorder, but it may also be accompanied by physical symptoms such as:

A. Fatigue and trembling
B. muscle tension
C. headache, and nausea
D. stomach pain
E. all of the above

Ans: E

46. a patient in stupor withdraws upon painful stimulation. What would be his score on the Glasgow coma scale?

A. M2
B. M4
C. M5
D. M1
E. M3

Ans: B

47. cognitive deficits of schizophrenia manifest themselves in which of the following phases of the disease?

A. Only in prodrome phase
B. In all phases of schizophrenia
C. Only in the first psychotic episode
D. Only when patient had depressive disorder
E. Only in the chronic phase after many episodes

Ans: B

48. in the attached figure which cells will describe the long-term depression and potentiation on that will involve structural changes in the presynaptic terminals of sensory neurons after one week of training?

A. Cell C has long term depression and cell B has long term potentiation
B. Cell A has long term depression and Cell C has long term potentiation
C. Cell A has long term depression and cell B has long term potentiation
D. Cell B has long term depression and cell C has long term potentiation

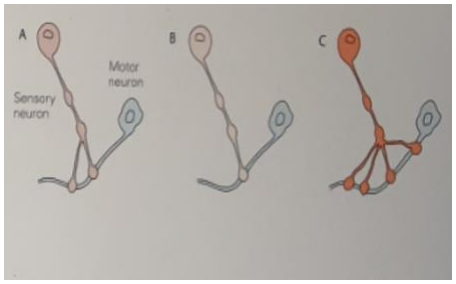

Ans: D

49. A 60-year old man was diagnosed with major depression after the loss of his wife. He feels guilty for outliving her and admits hearing her talking to him at night. Which of the following tricyclic antidepressants is best for treating with psychotic features?

A. Imipramine
B. Clomipramine
C. Doxepin
D. Desipramine
E. Amoxapine

Ans: E

50. A 20-year-old has an inherited progressive neural degeneration of brain. This resulted in twitching movements of head, grimacing movements in face and lips, and tongue, gesticulating movements in distal parts of upper limbs and jerking movements in distal part of lower limbs. The neurons in which of the following parts of the brain were degenerated in this case?

A. Subthalamus
B. Striatum
C. Globus pallidus interna
D. Substantia nigra compacta
E. Globus pallidus externa

Ans: B

51. Nociceptors are sensory receptors which respond to

A. Mechanical pressure
B. Sound waves
C. Tissue damage
D. Visible light
E. Taste

Ans: C

52. A 60-year-old presents with a headache for the last month, intensity is moderate aching and it is localized to right side of the head which of the following is most consistent with his condition?

A. Treated specifically by opioid analgesics.
B. Treatment should not exceed 3 months.
C. Loss of vision is a major complication.
D. Erythrocyte sedation rate of less than 30 mm/hr
E. It is a localized disorder and no systemic symptoms are expected.

Ans: C

53. which of the following sensory receptors monitor slippage of objects along the surface of the skin, allowing modulation of grip on an object?

A. Meissner's corpuscles
B. Pacinian corpuscles
C. Free nerve endings
D. Markel's discs
E. Ruffini endings

Ans: E

54. which of the following is a negative symptom of schizophrenia?

A. Word salad
B. Thought broadcasting
C. Hallucination
D. Thought blocking
E. Pressured thought

Ans: D

55. Treatment of ADHD is based on restoring the level of which of the following neurotransmitters?

A. ACTH and GABA
B. Noradrenaline and dopamine
C. Glutamate and GABA
D. Histamine and ACTH
E. Serotonin and orexin

Ans: B

56. Jenny, 56-year-old accountant, married with three children, she describes herself as "worrier" and has worried more (for the past 1 year) about her children's health, finance, marital relationship, and the future. Jenny is likely suffering from?

A. Clinical depression
B. Alcohol dependence
C. Generalized anxiety disorder
D. Adjustment disorder
E. Bipolar disorder

Ans: C

57. alcohol does which of the following?
A. increase Glutamate activity
B. increase serotonin in the frontal lobe
C. increase GABA activity
D. decrease dopamine in the reward system
E. activated the amygdala

Ans: C

58. a 30-year-old woman is brought to the hospital after an episode of weakness. On examination she has decreased strength in her left upper extremity and decreased light touch sensation over her right lower extremity. She has no decrease in mentation. A lumbar puncture was performed, and CSF contains elevated levels of IgG and oligoclonal bands on gel electrophoresis. Which of the following findings in the CSF is she most likely to have?
A. Perivascular lymphocytes with de myelinated axons in white matter
B. Gliosis with atrophy of the caudate and putamen
C. Loss of pigmented neurons in the substantia nigra
D. Foci of multinucleated cells and macrophages in gray and white matter
E. Increased neurofibrillary tangles and plaques in the neocortex

Ans: A

59. flat affect is part of which of the following:
A. obsessive compulsive disorder
B. positive symptoms of schizophrenia
C. negative symptoms of schizophrenia
D. anxiety disorder
E. manic phase of bipolar disorder

Ans: C

60. treatment with certain antipsychotic drugs produces extrapyramidal side effects. Which of the following movement disorders appears first in the progression of these side effects?
A. acute dystonia
B. bradykinesia
C. tardive dyskinesia
D. akathisia
E. rigidity

Ans: A – the question was appealed

61. Early treatment of ADHD results in:

A. increase risk of car accidents
B. increase risk of substance abuse
C. increase risk of criminal acts
D. increase risk of marital problems
E. help with maturation of the frontal lobe

Ans: E

62. Gary is a 35-year-old man who was previously healthy until one day, when he noticed that his right leg was weak. As the day progressed, he found that he was dragging the leg behind him when he walked. He noticed that his left leg felt a little bitt numb. Gray arrived at the emergency room of the hospital with significant difficulty in walking. Grays language function, cranial nerves, and sensory and motor examination of his arms where writhing normal limits. His right leg showed markedly weakness, with brisk reflexes in the knee and ankle, vibration and position sense in the right leg were absent. Pain and temperature testing were normal in the right leg but these sensations where absent in the left leg and abdomen to the level of the umbilicus. Reflexes in the left leg were normal, but when the physician scratched the lateral portion of the plantar surface on the bottom side of grays right foot, the great toe moved up. The remainder of grays examination was normal.
Gray's loss of left sided pain and temperature sensation could be due to damage of which part?

A. Right spinothalamic tract
B. Right fasciculus gracilis
C. Left spinothalamic tract
D. Right fasciculus cuneatus
E. Left corticospinal tract

Ans: A

63. bulimia nervosa is characterized by which of the following?

A. they are usually introverted
B. refusal to maintain weight over minimal normal weight
C. eating usually causes severe anxiety
D. distorted body image-feeling fat even when emaciated
E. menstrual cycle is usually intact

Ans: E

64. 22-year-old Zafar had multiple stab wounds in the back while resisting an attempt robbery, an MRI done the next day shown a hemi-section of the spinal cord at the level of the left T6 vertebrae. Which of the following spinal segments corresponds to the T6 vertebrae?

A. L1
B. T10
C. T8
D. T11

E. T9

Ans: C

65. tension type headache is characterized by:
A. nausea and vomiting
B. aggravated by walking
C. unilateral localization
D. change in vision
E. moderate intensity

Ans: E

66. A 56-year-old man with higher than normal language output and frequent paraphasic errors. Testing reveals that his comprehension of auditory and visual language is severely disturbed. He also exhibits inability to repeat language. This patient had which of the following aphasia?
A. global
B. transcortical
C. conduction
D. Wernicke's
E. Broca's

Ans: D

67. foods with high tyramine like cheese should not be consumed with which type of antidepressant?
A. Atypical
B. SNRI
C. TCA
D. MAOI
E. SSRI

Ans: D

68. Which of the following tracts is involved in Horner's syndrome?
A. Corticospinal
B. spinothalamic
C. hypothalamospinal
D. spinocerebellar
E. tectospinal

Ans: C

69. A 50-year-old alcoholic man presented with leg ataxia. An MRI of the brain and spinal cord would show degeneration of which of the following structure?
A. anterior paravermal cerebellum
B. lateral medullary
C. lateral part of the lumbosacral spinal cord

D. lateral part of the cervical spinal cord

Ans: A

70. A 27 years old female is being transcribed clomipramine for major depression. Which of the following side effects she should be counseled about?

A. excessive urination
B. miosis
C. blurred vision
D. diarrhea
E. excessive salivation

Ans: C

71. Pain receptors are present in which of the following. Structures in the head?

A. Dura matter
B. thalamus
C. hypothalamus
D. brainstem

Ans: A

72. The T2-weighted MRI scan on the left side of the figure is of a normal patient. In the CT scan on the right side, the patient had sustained a right cerebral hemorrhage, indicated by the large white area. Which of the following blood vessel(s) would be affected in this case?

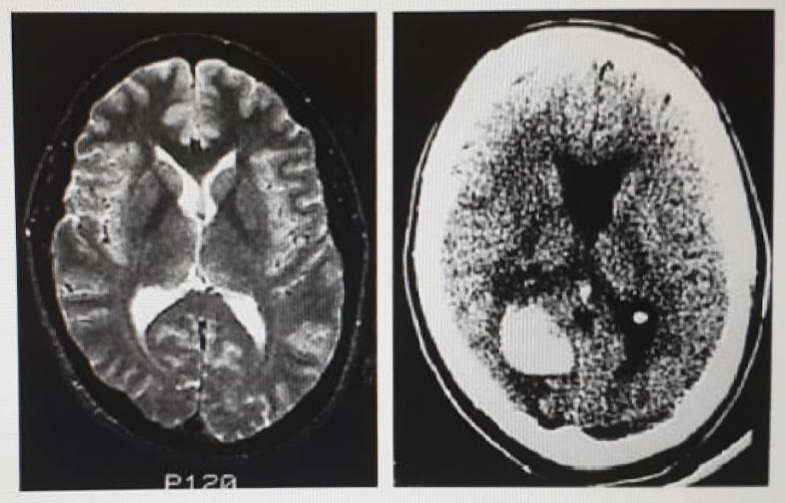

A. striate arteries
B. superior cerebellar artery
C. posterior cerebral artery
D. anterior cerebral artery
E. middle cerebral artery

Ans: C

73. a 60-year-old patient with sudden onset of abnormal movements in his right limbs came to KFSHRC. He had increased appetite and hyperphagia and also developed mood and behavioral changes. Mental status and cranial nerves function were normal. In examination of motor system, no abnormality was detected in muscle tone, and force of extremities was normal. Deep tendon reflexes were symmetric, and no pathologic reflexes were found. Involuntary movements, including continuous, arrhythmic and purposeless choreiform movements with occasional brisk proximal ballistic movements were seen affecting both upper and lower limbs on the right side with the same severity. The magnetic resonance showed an infarct in the sub-thalamic region. He is suffering from which one of the following conditions.
    A. Alzheimer's disease
    B. Huntington's chorea
    C. Sydenham's chorea
    D. Hemiballismus
    E. Parkinson's disease

Ans: D

74. A 46-year-old bank executive presented with stress and insomnia. In order to combat stressful situations, he frequently takes some alcohol before going to bed. The physician prescribed diazepam to him. On a very stressful night, patient ingested high dose of diazepam followed by alcohol. He continued to take alcohol till he became unconscious. He was brought to hospital by the family with very slow respiration and heart rate. Which one of the following drugs can be used to treat this patient?

A. Flumazenil
B. Clonidine
C. Methadone
D. Amphetamine
E. Naloxone

Ans: A

75. A 30-year-old woman complains of unsteadiness while standing and walking. She tends to deviate to the left. Neurologic examination reveals dysmetria on the left side, dysdiadochokinesia, and nystagmus that is more marked when she looks to the left side. Where is the lesion located?

A. left cerebellar hemisphere
B. left striatum
C. left globus pallidus
D. right cerebellar hemisphere
E. right substantia nigra

Ans: A

76. A 62-year-old female with chronic psychiatric disorder claims that the comment of a well-known news anchorman has a special meaning that only she understands. She is

convinced that that when he reports on local event, he is really trying to persuade her to start a (Sinful relationship) this is an example of:

A. visual hallucination
B. a delusion of persecution
C. delusion of reference
D. concrete thinking
E. an illusion

Ans: C

77. A 50-year-old hypertensive woman complains of numbness and weakness in her leg and foot. Occlusion of which of the following vessels may account for this complaint?

A. anterior cerebral artery
B. posterior cerebral artery
C. internal carotid artery
D. anterior choroidal artery
E. middle cerebral artery

Ans: A

78. A 72-year-old alcoholic woman had problems in remembering things for past one year. Her immediate family member noticed that she confabulates quite often. She dies as consequence of hepatic failure. At autopsy morphological changes are seen in mammillary bodies and medial dorsal nucleus of the thalamus. Which of the following is the most likely diagnosis in this case?

A. multiple system atrophy
B. Wernicke-Korsakoff syndrome
C. central pontine myelinolysis
D. pick disease
E. metachromatic leukodystrophy

Ans: B

79. which one of the following cellular events will occur in long term depression?

A. more AMPA receptors will be inserted
B. calcineurin will be activated
C. CAMKII will be activated
D. NR2A subunits of NMDA receptors in hippocampus
E. high postsynaptic Ca2+

Ans: B

80. which of the following is a manifestation of increased intracranial pressure?

A. Miosis
B. Anosmia
C. Arterial hypotension
D. Decreased score on Glasgow Coma score
E. Tachycardia

Ans: D

81. Descending neurons from which of the following structures is involved in the modulation of pain via the release of serotonin?

A. Locus coeruleus
B. Periaqueductal gray area
C. Periventricular area
D. Interneurons of the spinal cord
E. Nucleus raphe magnus

Ans: E

82. A 54 old man with 3-month history of headaches is brought to emergency department following a generalized tonic-clonic seizure. On physical examination, he has weakness on the right side. An MRI of his brain shows a large irregular 6-cm mass in the left cerebral hemisphere that extends across the corpus callosum. A stereotaxic biopsy of the mass is done, and histological findings are shown in the figure. Which of the following neoplasms is the most likely to have?

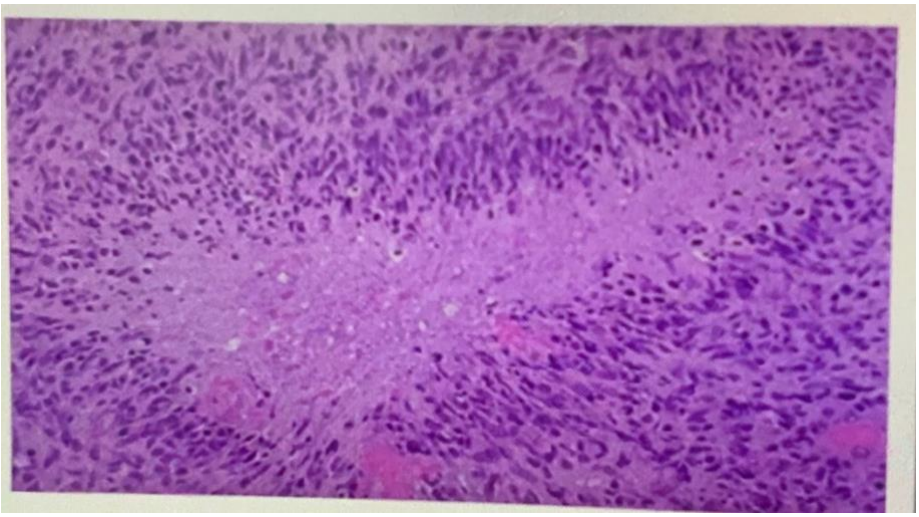

A. Hemangioblastoma
B. Diffuse large B-cell lymphoma
C. Glioblastoma multiform
D. Medulloblastoma
E. Meningioma

Ans: C

83. which of the following is the most common type of hallucinations in schizophrenia ?

A. Auditory
B. Tactile
C. Olfactory
D. Gustatory
E. Visual

Ans: A

84. the amygdala is crucial for which of the following learning pathways?
A. Priming
B. Non-associative learning
C. Skills and habits
D. Associative learning

Ans: D

85. the attached diagram shows frequency of events as detected from a sensory receptor in response to a stimulus. Based on the profile of the activity, which of the following receptors is likely to show this response?

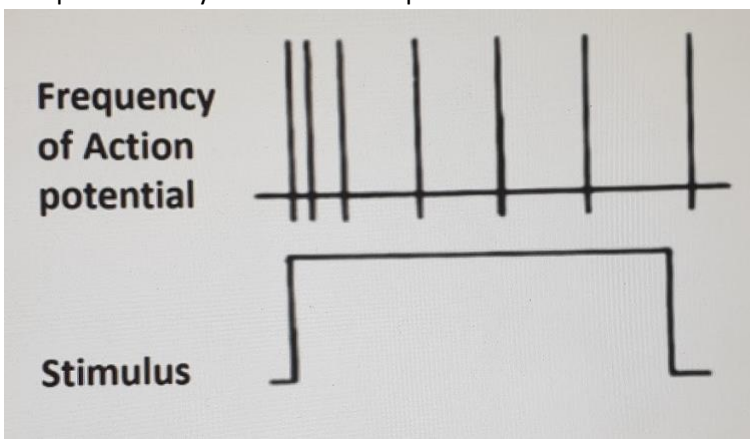

A. Pacinian corpuscle
B. Meissner corpuscle
C. Muscle spindle
D. A delta type ll free nerve endings
E. Hair receptors

Ans: C

86. what is the clinical indication of varenicline?
A. Sedative – hypnotic
B. Mood stabilizing agent
C. Migraine
D. Antidepressant
E. Smoking cessation aid

Ans: E

87. which of the following is the most common cause of death by cocaine use?
A. Heart attack, or stroke
B. Hypothermia
C. Decreased motor activity
D. Decreased blood pressure
E. All of the above

Ans: A

88. 62-year-old man has had increasing difficulty with voluntary movements because of muscle rigidity. On physical examination he has difficulty initiating the movement. He has expressionless facies. When he is sitting, his hands have a “pill—rolling” tremor. Which pathologic finding in the brain is most likely to be present?

A. Loss of pigmented neurons in the substantia nigra
B. Neuronal loss with gliosis in the caudate
C. Hemosiderosis and gliosis of mamillary bodies
D. Alzheimer type 2 gliosis in basal ganglia
E. Hippocampal neurofibrillary tangles

Ans: A

89. Which one of the following is the function of the cerebrocerebellar?
    A. Correction of balance
    B. Correction of muscle tone
    C. Correction of motor planning
    D. Initiating movements
    E. correction of the execution of movement

Ans: C

90. A pouting and demanding 25-year-old woman begin psychotherapy stating that she is both desperate and bored. She recounts a five-year-old history of short episodic bursts of anxiety and depression, several theatrical suicidal gestures, impulsive and self-defeating behavior. She has abruptly terminated two previous attempts at psychotherapy. Her mental status exam showed her reality testing to be intact. What would be the next step in her management?

A. Discharge patient home and tell her to call if she develops any suicidal thoughts in the future
B. Start fluoxetine for mood swings
C. Assess risk of suicide, and make safety planning
D. start CBT
E. give her anxiolytic like alprazolam

Ans: C

91. A 35- year old female with frequent migraine attacks present to the emergency department complaining that her abortive migraine treatment have not been working recently and her attacks are causing disability in her day to day life as she has not been able to go to work or be productive. The resident physician decides that she is eligible for preventive treatment and notes that she’s epileptic, which of the following is the medication of choice in her case?

A. Timolol
B. Topiramate
C. Ibuprofen

D. Amitriptyline
E. Ergotamine

Ans: D

92. Gary is a 35 year old man who was previously healthy until one day, when he noticed that his right leg was weak. As the day progressed, he found that he was dragging the leg behind him when he walked. He also noticed that his left leg felt a little bit numb. Gary arrived at the emergency room of hospital with significant difficulty in walking. On physical examination, Gary's language function, cranial nerves, and motor and sensory examination of his arms were within normal limits. His right leg showed markedly weakness, with very brisk reflexes I the knee and ankle. Vibration and position sense in the right leg were absent. Pain and temperature testing were normal in the right leg but these sensations were absent on the left leg and abdomen to the level of his umbilicus. Reflexes In the left leg were normal, but when the physician scratched the lateral portion of the plantar surface on the bottom side of Gary's right foot, the great toe moved up. The remainder of his examination was normal. The upward movement of Gary's toe when the plantar surface of his foot was scratched is an indicative of a lesion in which portion of the nervous system?
    A. Saphenous nerve
    B. Sural nerve
    C. LMN
    D. peripheral nerves
    E. UMN

Ans: E

93. A 65-year-old woman who fell to the ground and hit her head is taken to the ER. Physical examination is unremarkable. CT scan of the head shows no hemorrhage or fracture, but there is a 5cm mass beneath the dura that compresses the underlying right parietal lobe. The mass is surgically removed. Histologic sections from the mass would most likely reveal:

A. Whorls of meningeoepithelial cells and scattered psammoma bodies
B. sheets of anaplastic small blue cells with Homer-Wright rosettes
C. Antoni A areas and Antoni B areas with Verocay bodies
D. Endothelial proliferation and nuclear pseudo palisading around necrotic area
E. fried egg appearance of tumor cells with scattered calcification

Ans: A

94. On non-contrast CT of the brain, acute hemorrhage is:

A. Isodense to CSF
B. Hypodense to fat
C. Hypodense to brain parenchyma
D. Hyperdense to bone
E. Hyperdense to the brain parenchyma

Ans: E

95. a 14-year-old child came to the neurologic clinic with progressive weakness of both lower limbs. Two weeks back he had diarrhea which was treated. On clinical examination, he has flaccid type of weakness in both lower limbs with loss of knee jerk bilaterally. What was his weakness most probably due to?

A. demyelination of peripheral nerves
B. demyelination of corticospinal pathways
C. Degeneration of anterior grey horn cells
D. degeneration of corticospinal pathways
E. degeneration of posterior white column

Ans: C

96. A patient is brought into the emergency department due to a road traffic accident and plain CT was performed. Which of the following types of hemorrhage is unlikely to be due to trauma?

A. intraventricular hemorrhage
B. subdural hemorrhage
C. subarachnoid hemorrhage
D. epidural hemorrhage
E. basal ganglia hemorrhage

Ans: C & E – the question was appealed

97. A 20-year-old university patient presents with symptoms which lasted for 2 months and got worse in the last 2 weeks, she starts many projects but doesn't finish them and gets distracted easily, which has affected her grades. She sleeps less but doesn't feel tired. She is impulsively buying unnecessary things online. Her friends say she's unpredictable and gets too excited or too angry over little things. What is the management for her?

A. Cognitive Behavioral Therapy
B. Zolpidem to help with sleep
C. Antidepressant like escitalopram
D. Anxiolytic like diazepam
E. Young mania rating scale to rule out bipolar

Ans: E

98. A 72-year-old has been unable to live independently alone for the past 5 years. On physical exam there was no motor or sensory loss. He cannot give the current date or state in which he is in. He develops aspiration pneumonia and dies after one year. A picture of the brain is shown with frontal atrophy. Which of the following is the mechanism of disease?

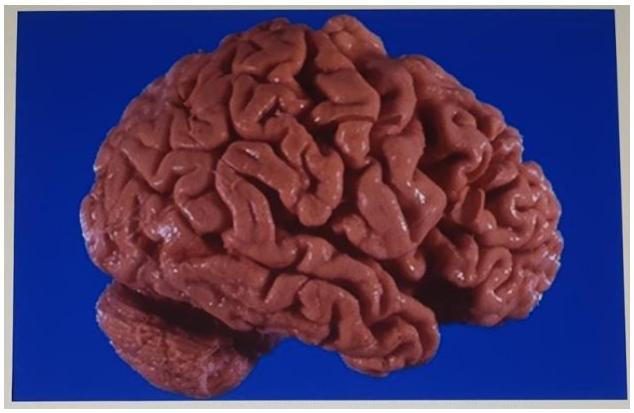

A. AB Peptide aggregation
B. Tau gene mutations
C. CAG repeat expansion
D. Dopamine deficiency
E. Conformational change in prion protein (PrP)

Ans: A

99. Which of these CNS infections has this epidemiological distribution shown?

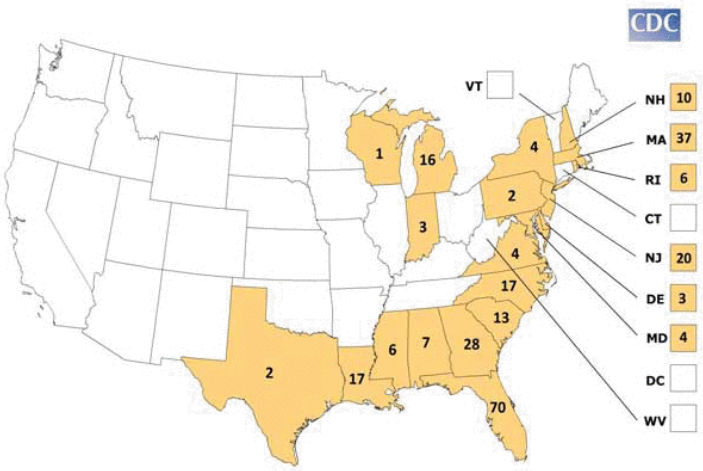

A. West Nile encephalitis
B. Japanese encephalitis
C. Coxsackie virus
D. Eastern equine encephalitis
E. Polio type 2

Ans: D

100. During development of the medulla the general visceral efferent develop into which of the following nuclei?

A. Ambiguus
B. Solitarius
C. Dorsal Vagal

D. Cochlear
E. Hypoglossal

Ans: C

101. A heroin addict is brought in while under effect to the ER due to a road traffic accident. The patient fractured their humerus. Patient was injected with pentazocine. What is the outcome?

A. Euphoria
B. Respiratory depression
C. Miosis
D. Development of withdrawal symptoms
E. Synergistic analgesic effect with heroin

Ans: D

102. What is the tingling sensation associated with multiple sclerosis when the patient flexes their neck?

A. Requires urgent treatment
B. Indicates periventricular lesion
C. Normal in unaffected individuals
D. Uthoff phenomenon
E. Lhermitte phenomenon

Ans: E

103. A 47-year-old woman has not been feeling like herself for the past 6-8 months and is unable to enjoy anything. She feels sad and anxious. Has difficulty sleeping and is always tired. She has decreased appetite and has lost 10 kgs in 6 months. What's the best approach?

A. Start antidepressants
B. Anxiolytic like Diazepam
C. Advise the patient and tell her it's part of life and not to worry
D. Start sleeping pill for 2 weeks (zolpidem)
E. More detailed history to rule out bipolar

Ans: E

104. Encoding of new memory in the hippocampus requires long term potentiation (LTP) of synaptic function. Which of the following neurotransmitter is essential in the initiation of this process?

A. dopamine
B. nitric oxide
C. glutamate
D. acetylcholine
E. norepinephrine

Ans: C

105. 62-year-old patient presented with severe dyspnea. He is a known case of congestive cardiac failure. He was administered morphine. What is the rationale of using morphine in this case?

A. Decreases venous return and hence preload Reduces sympathetic tone
B. Reduce sympathetic tone in CNS
C. Revels pulmonary edema by diuretic action
D. Increase cardiac output by activating mu restores
E. causes bronchodilation

Ans: A

106. Which of the following correctly describe the relationship of CSF pressure to the venous pressure in the superior sagittal sinus?

A. equal to
B. few millimeters lower
C. few millimeters higher
D. one half the value
E. twice the value

Ans: C

107. which antiparkinsonian drug from the following might be responsible for the abnormality shown in the picture?

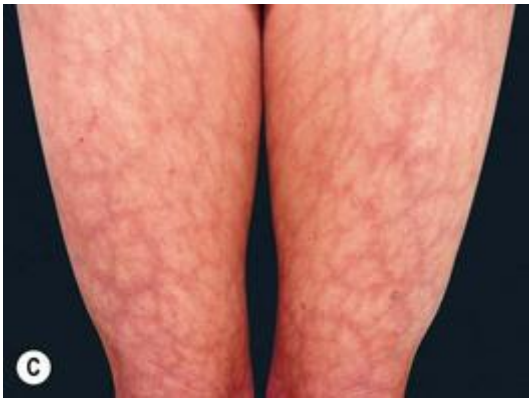

A. amantadine
B. apomorphine
C. levodopa and carbidopa
D. tolcapone
E. bromocriptine

Ans: A

108. which of the following regions of the body has the largest representation in the primary motor cortex (Brodmann area 4)?

A. forearm
B. thumb

C. trunk
D. mastication muscles

Ans: B

109. which of the following agents is most likely associated with increase lymphocyte and increase protein and normal glucose of the CSF

A. mycobacterium TB
B. cryptococcus neoformans
C. aspergillus spp
D. Japanese encephalitis virus
E. streptococcus pneumonia

Ans: D